



PATIENT

Mathew Moyet

SPECIES

Canine

BREED

Maltese Mix

SEX

Male Neutered

AGE

12 years

WEIGHT

8lbs

INTERPRETED BY

Maggie Machen Lamy,
DVM, DACVIM
(Cardiology)

IMAGING PERFORMED BY

G. Ferrer, DVM

HOSPITAL NAME

Paseos Veterinary
Center

REFERRING VET

Dr. Torres

INVOICE

24255

DATE

5/18/22

PRESENTING CLINICAL SIGNS

History: Presented as a referral for evaluation of the heart as rDVM auscultated a grade 3-4/6 systolic HM. This patient has early renal insufficiency.

-Current medications: Previously on furosemide and enalapril but stopped on 5-9-22. Started Pimobendan 1mg BID on 5-11-22. Currently on K/D diet as of 5-9-22.

-Abnormal PE/Chem/CBC/UA Results: Normal BW: 5-11-22 AMY: 1318 (200-1200) BUN: 40 (7.0-25) Creat: 2.1 (0.3- 1.4) on 5-9-22 was 2.7 Glucose: 111 (50-110)

ECHOCARDIOGRAM FINDINGS

2D, m-mode, color flow and doppler imaging is available. Diffuse thickening of mitral valve leaflets (anterior>posterior) with prolapse into the left atrial lumen. Moderate eccentric mitral regurgitation with moderate left atrial dilation. Normal MR velocity. Mildly increased LV diameter with adequate myocardial function. The tricuspid valve appears mildly thickened with mild tricuspid regurgitation. Normal velocity. Normal right atrial and ventricular diameter. The pulmonic valve is normal in morphology and mobility. Mild aortic valve thickening. Normal pulmonic and aortic outflow velocities. No aortic or pulmonic insufficiency. No pericardial or pleural effusion noted. No cardiac tumors observed.

CARDIAC CHART

| CANINE CARDIAC PARAMETERS | MR VMAX (m/s) | TR VMAX (m/s) | LA/AO (Boon method) | LA/AO (Heart Base; Swe) | FS (%) | EF (%) | EPSS (cm) |
|---|---------------|---------------|---------------------|-------------------------|---------------------------------|--|--|
| NORMAL PARAMETER | 4.5-5.5 | <2.7 | 1.3 | <1.6 | 28-40 | 40-100 | <0.6 |
| PATIENT | 5.5 | 2.3 | NM | 1.6 | 56 | 88 | 0.3 |
| CANINE CARDIAC PARAMETERS | HR (BPM) | AV VMAX (m/s) | PV MAX (m/s) | BODY WEIGHT (kg) | LA 2D short axis Base view (cm) | LVIDd Avg; 2D and m-mode short axis (cm) | LVIDs Avg; 2D and m-mode short axis (cm) |
| NORMAL PARAMETER | 50-100 | 0.7-1.7 | 0.7-1.6 | BELOW | BELOW | BELOW | BELOW |
| PATIENT | 180 | 0.7 | 0.86 | 3.6 | 1.8 | 2.5 | 1.0 |
| *Normal chamber parameters expressed as a mean value (SD) | | | | 3 | 1.27 (5.3) | 2.46 (2.46) | 1.36 (5.5) |
| BODY WEIGHT DEPENDENT PARAMETERS | | | | 5 | 1.40 (4.5) | 2.74 (5.2) | 1.60 (4.7) |
| <i>*Note: All measurements based upon multi-modal images and methods. An average value is reported.</i> | | | | 10 | 1.50 (3.8) | 3.27 (3.5) | 2.06 (3.1) |
| | | | | 15 | 1.83 (2.0) | 3.71 (2.4) | 2.43 (2.1) |
| | | | | 20 | 2.02 (1.9) | 4.14 (2.2) | 2.80 (2.0) |
| | | | | 25 | 2.18 (2.4) | 4.48 (2.9) | 3.10 (2.5) |
| | | | | 30 | 2.33 (3.3) | 4.83 (3.9) | 3.39 (3.4) |
| | | | | 35 | 2.48 (4.3) | 5.17 (5.0) | 3.69 (4.5) |
| | | | | 40 | 2.62 (5.2) | 5.48 (6.1) | 3.96 (5.4) |
| | | | | 50 | 2.88 (7.1) | 6.07 (8.3) | 4.46 (7.4) |

INTERPRETATION OF THE FINDINGS & FURTHER RECOMMENDATIONS

Chronic degenerative valve disease causing moderate mitral and mild tricuspid regurgitation. Moderate left atrial enlargement indicates there is relatively low risk for imminent complication, however risk for progression to spontaneous congestive heart failure in the future is elevated. The aortic valve is mildly thickened, and a baseline blood pressure is strongly recommended. No additional issues are identified.



PATIENT

Mathew Moyet

SPECIES

Canine

BREED

Maltese Mix

SEX

Male Neutered

AGE

12 years

WEIGHT

8lbs

INTERPRETED BY

Maggie Machen Lamy,
DVM, DACVIM
(Cardiology)

IMAGING PERFORMED BY

G. Ferrer, DVM

HOSPITAL NAME

Paseos Veterinary
Center

REFERRING VET

Dr. Torres

INVOICE

24255

DATE

5/18/22

Given these findings, it is reasonable to continue Pimobendan going forward. No obvious indication for Lasix or ACE-I therapy, particularly in light of azotemia. These should only be utilized if and when congestive heart failure is confirmed in the future. Assessment of progression in the future will help predict long term outcome, however prognosis is guarded at this stage (B2).

Omega fatty acid supplementation and mild salt restriction may also be of some long-term benefit. Monitor for development of a progressive cough, labored breathing, exercise intolerance or collapse episodes.

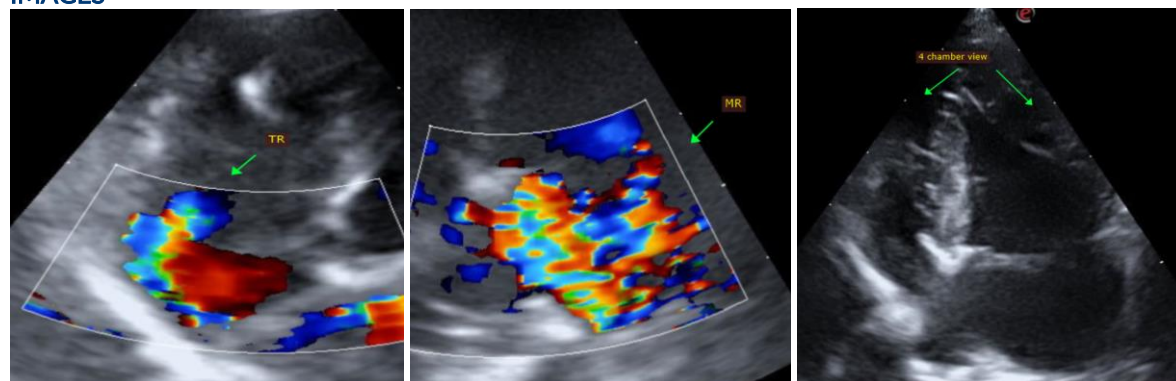
Once on the medication for 3-5 days, anesthetic risk is considered mildly elevated. Cardiac protective drug choices (opioid/benzodiazepine premedication, Propofol or alfaxalone induction, iso or sevo gas) are recommended. Monitor for arrhythmias, hypotension, and hypoxia both intra and post-operatively and intervene as necessary. Judicious IV fluid rates are recommended to avoid fluid overload. Avoid heart rate stimulating drugs such as atropine unless clinically indicated.

PLAN

Baseline BP recommended. Institute heart muscle support Pimobendan 0.25-0.3mg/kg PO q12h.

Recommend monitor for progression with a recheck echocardiogram in 6 months, sooner if any development of clinical signs.

IMAGES



The information and recommendations provided are based on the images presented by the referring veterinarian. No evaluation can be communicated regarding pathology that was not visible in the image/video clips provided.

Thank you for this referral. This report was generated using transcription software, and minor dictation errors may be present. If the clinical or image interpretation does not parallel your findings or if I can be of any further assistance, please contact me.

Maggie Machen Lamy, DVM
Diplomate of the American College of Veterinary Internal Medicine (Cardiology)
info@sonopath.com